

# **Bisphosphonates in Oral Diseases: Updates of its implications in Dental Management**

Jayalakshmi K\* Ravikumar† H Jaya Naidu‡ Archana Patil§

\*MDS, Professor, §MDS, Senior Lecturer, Department of Oral Pathology and Microbiology, †MD, Assistant Professor, Department of General Surgery, ‡MDS, Professor, Dept. of Paedodontics, Vydehi Institute of Dental Sciences, Bangalore, Karnataka, India. Email: kswmy@rediffmail.com

## **Abstract:**

Bisphosphonates are synthetic analogs of naturally occurring pyrophosphates, and they inhibit bone resorption and therefore improve bone mineral density by decreasing bone turn over. For this reason, it has a wide application in oral diseases, such as oral cancer, breast cancer, osteogenesis imperfecta, fibrous dysplasia, hypercalcemia etc. But this drug has its own adverse effects. Osteonecrosis of the jaws is a major complication associated with long-term use of bisphosphonates. We aimed to summarize the structure of bisphosphonates, its applications, adverse effects, prevention and implications in dental management. The purpose of this review is to identify what new information has been gained over the past ten years and to provide opinion of its implications in dental management.

**Keywords:** Bisphosphonates, osteonecrosis, osteoporosis.

## **Introduction:**

Bisphosphonates were initially used either as corrosion inhibitors or as complexing agents in the textile, fertilizer or oil industries. It was shown in the 1960s that pyrophosphate inhibits calcification of tissues by binding to hydroxapatite but that orally administered pyrophosphates are hydrolyzed in the gut. The first report of the biological characteristics of bisphosphonates was published in 1968. Bisphosphonates are resistant to hydrolysis and so could be administered orally. The first bisphosphonate used for human treatment was etidronate for myositis ossification. It was discovered that bisphosphonates inhibited osteoclastic-mediated bone resorption and this led to their use as bone protective agents.<sup>[1]</sup> Bisphosphonates may carry a potential for severe suppression of

*P- ISSN*  
*0976 – 7428*

*E- ISSN*  
*0976 – 1799*

*Journal of  
International  
Oral Health*

*Oral Pathology*

*Review Article*

*Received: Jan, 2012*

*Accepted: May, 2012*

## **Bibliographic listing:**

*EBSCO Publishing*

*Database, Index*

*Copernicus, Genamics*

*Journalseek Database,*

*Proquest, Open J Gate.*

bone turnover that may impair some of bone's biomechanical and reparative properties.<sup>[2]</sup> Bisphosphonates have undergone considerable evolution since the early 1970s and the potency of these compounds has been steadily improved with each successive generation.

#### *Mechanism of action of bisphosphonates:*

The possible mechanism of action is that these drugs hinder the resorption of bone by inhibition of osteoclastic activity.<sup>[3,4]</sup> Other possible actions could be inhibition of osteoclast development from monocytes, increased osteoclastic apoptosis and prevention of osteoclasts development from bone marrow precursors. These drugs are known to down-regulate matrix metalloproteinases<sup>[4]</sup>, also these drugs hinder the bone blood flow<sup>[5]</sup> and also bisphosphonates are effective in inhibiting endothelial cells.<sup>[6]</sup>

#### *Band – wagon effect:*

The synergistic effect of the combination of chemotherapy, bisphosphonate-induced cellular stress due to long term use, cancer related co-morbid factors, uncoupling of osteoblast – osteoclast equilibrium, reduced vasculature, bone microfractures, and tracking of oral microbes through the periodontium may act in concert to produce a 'bandwagon effect' that raises disease burden and lower susceptibilities threshold in favor of BJON.<sup>[3]</sup>

Gene variability was reviewed in depth to give a clinical illustration on the genetic aspects of bisphosphonate – related osteonecrosis. Among genetic factors, polymorphisms of CYP2C8 gene arise as a promising risk factor. BJON can be predicted with a conjunction of genetic and environmental risk factors.<sup>[7]</sup>

#### *Applications:*

Bisphosphonates can be applied to the diseases associated with pathological effects on the skeleton that is osteopathy, those associated with hypercalcemia and other conditions associated with soft tissue calcification, calcinosis.<sup>[2,8,9]</sup> Intravenous bisphosphonates are used to reduce bone pain, hypercalcemia of malignancy, osteogenesis imperfecta and skeletal complications in patients with multiple myeloma, breast, lung and other cancers, Paget's disease of bone and osteoporosis of postmenopausal women<sup>[2,9]</sup> and corticosteroid-induced bone loss. Consequently, improve the quality of life for the patients.

Bisphosphonates are also used in conditions associated with calcinosis in paediatric practice such as dermatomyositis, fibrodysplasia ossificans progressiva, scleroderma, fibrous dysplasia and idiopathic hyperphosphatasia.<sup>[8]</sup>

#### *Structure and Properties of bisphosphonates*

Bisphosphonates are chemical analogues of pyrophosphate. The presence of a carbon rather than oxygen atom at the center of the molecule prevents its breakdown. The two phosphonate groups are attached directly to the carbon atom from which also extend the R1 and R2 side chain [Fig. 1]. The R1 side chain is usually hydroxyl group and is often referred to as the "bone hook" in association with the phosphonic groups.

Generally Bisphosphonates have high affinity for hydroxyapatite, remaining unmetabolized for long periods of time. The older Biphosphonates, etidronate and clodronate, form cytotoxic acyclic ATP analogues which accumulate in osteoclasts, leading to apoptosis.<sup>[3]</sup>

The commonly used nitrogen containing Biphosphonates comprise pamidronate, olpadronate ibandronate, alendronate, risedronate and Zoledronate.<sup>[9]</sup> Bisphosphonates also inhibit osteoclastic activity indirectly through bone marrow stromal cells and osteoblasts. Bisphosphonates inhibit RANKL expression and enhance OPG production by bone marrow stromal cells and osteoblasts, so that RANK – RANKL interaction is disrupted. These synergistic actions lead to suppression of osteoclast recruitment and reduction of bone resorption.<sup>[3]</sup>

Clodronate is the only bisphosphonate currently available as oral formulation for the treatment of metastatic bone disease.<sup>[10]</sup> Clodronate is less effective against skeletal complications than i.v. pamidronate.<sup>[10]</sup> Clodronate, an alkyl bisphosphonates are less potent, a high cumulative dose through long term exposure would appear to be necessary and would favor osteonecrosis of the Jaw (ONJ).<sup>[11]</sup> Alendronate is a nitrogen containing orally administered bisphosphonate that was approved by the FDA in USA since 1995.<sup>[3]</sup> Pamidronate is a nitrogen-containing bisphosphonate with an aminogroup attached at the R<sup>1</sup> position. It is one of two bisphosphonates approved by the FDA for intravenous administration.<sup>[3]</sup>

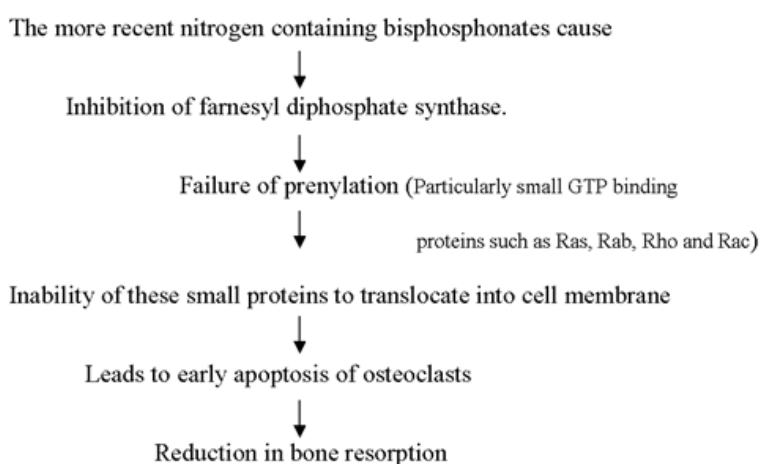
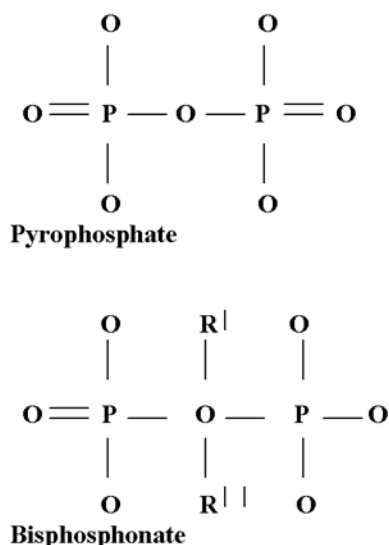
Zoledronic acid is also a nitrogen-containing bisphosphonate with an imidazole ring attached at the R<sup>1</sup> position.<sup>[12]</sup> Risedronate is also a nitrogen-

containing bisphosphonate with high affinity for hydroxyapatite. It appears to have better gastro intestinal tolerability than Alendronate and may be preferred for patients in whom this is a concern.<sup>[13]</sup> Ibandronate is a third-generation nitrogen containing oral bisphosphonate. In 2005, it became the first FDA-approved bisphosphonate to be taken once a month. It is administered orally, as well as intravenously.<sup>[10]</sup>

Etidronate does not contain nitrogen. Unlike other bisphosphonates, etidronate increases bone density by acting directly on bone and not through

osteoclasts or osteoblasts.<sup>[3]</sup> Tiludronate also, does not contain nitrogen. It prevents bone resorption by inhibiting osteoclast activity.<sup>[3]</sup>

Other bisphosphonates include EB-1053, icandronate, minodronate, neridronate and olpadronate. Clodronate, an alkyl bisphosphonate, also induces ONJ.<sup>[11]</sup> Intravenous formulations of neridronate and olpadronate are being tested in patients with breast cancer and Paget's disease, respectively.<sup>[3]</sup> The brief description of different bisphosphonates is summarized in Table 1.



**Fig.1, Structure of bisphosphonate**

#### *Adverse effects of bisphosphonates:*

Bisphosphonates are administered either orally or via an intravenous infusion. The oral administration of bisphosphonates is limited by poor bioavailability and gastrointestinal (GI) toxicities (Primarily esophagitis and diarrhoea).<sup>[8]</sup> Long term use of oral bisphosphonates may increase the risk of esophageal cancer.<sup>[14,15]</sup>

Intravenous administration is associated with mild- to-moderate flu-like symptoms following the initial infusions, whereas oral administration is associated with a significant incidence of GI adverse events. Oral administration is generally not associated with adverse effects on renal function, whereas renal function can be affected by i.v. administration.<sup>[8]</sup> The acute phase reaction with intravenous administration was characterized by high temperature, musculoskeletal

aches and vomiting in about 85% of patients. A slower healing of wound and under-tubulation at the growing ends of long bones with an appearance, not dissimilar to that seen in osteopetrosis which presumably had resulted from failure to remodel the metaphyseal diaphyseal junction.<sup>[9]</sup>

#### *Bisphosphonate intolerance:*

Too often we attribute symptoms to drugs without considering other causes. A study showed that patients who are intolerant of oral bisphosphonates are significantly more likely to be *H. pylori* positive.<sup>[16]</sup>

#### *Dental implications of bisphosphonate therapy:*

The majority of reported cases of BJON have been diagnosed after dental procedures such as tooth extraction. Less commonly, BJON appears to occur spontaneously in patients taking these drugs.<sup>[2]</sup>

#### *General considerations:*

The dentist must know the patient's history and susceptibility to oral disease. In this position the

dentist can imply treatment in the interest of

**Table 1. Description of commonly used bisphosphonates.**

Generic name	Brand name	Route of administration	Dosage	Indications	Side effects	Role in dentistry
Clodronate	-	Oral	1040/1600mg/day	Metastatic bone disease	Nausea, Diarrhoea	Metastatic tumors of the Jaw
Alendronate sodium	Fosamax	Oral	10mg/day	Osteoporosis in postmenopausal women, , Paget's disease	Hypocalcaemia, hypophosphatasia, intolerance, headache	Glucocorticoid induced osteoporosis of the Jaws
Etidronate disodium	Didronel	Oral	20mg/kg/day	Osteoporosis, Paget's disease, Heterotopic ossification	Fever, increased serum creatinine, intolerance, bone pain	Osteoporosis
Ibandronate sodium	Boniva	Oral/Intravenous	2-5mg/day	Osteoporosis, Postmenopausal women, Breast cancer, multiple myeloma.	Bone pain, hypercholesterolemia, gastrointestinal intolerance	Osteoporosis
Pamidronate disodium	Aredia	Intravenous	60-90mg ,Single dose	Cancer-associated hypercalcemia, Paget's disease, multiple myeloma	Hypokalemia, infusion site infection, nausea, hypophosphatemia	Osteolytic bone metastases of cancers such as breast cancer and multiple myeloma.
Risedronate sodium	Actonel	Oral	5mg/day	Postmenopausal osteoporosis, Paget's disease	Back pain, hypertension, rash, arthralgia, gastrointestinal intolerance, pain	Glucocorticoid-induced osteoporosis
Tiludronate disodium	Skelid	Oral	400mg/day	Paget's disease	Sinusitis paresthesia, chest pain, gastrointestinal intolerance	----
Zoledronic acid	Zometa	Intravenous	4mg IV for 15 mints	Osteolytic bone metastases of cancers such as breast cancer and multiple myeloma	Fever, fatigue, gastrointestinal intolerance	Cancer-associated hypercalcemia, Osteolytic bone metastases of cancers such as breast cancer and multiple myeloma

patients. For this reason, expert panel recommendations are intended to provide guidance, and are not a standard care, requirements or regulations based on scientific evidence.<sup>[2]</sup> Patients on bisphosphonates, and physicians prescribing them should be educated on potential oral complications and risks of BJON.<sup>[3,17]</sup> BJON can occur spontaneously, owing to dental disease or secondary to dental therapy. But in one study the author has stated that bisphosphonates was not associated with occurrence of BJON.<sup>[18]</sup> If possible bisphosphonate therapy should be delayed when dental health is sub-optimal. Invasive dental

procedures should be completed; non-restorable teeth with poor prognosis should be extracted.<sup>[3]</sup> Patients are still instructed to keep taking bisphosphonates for an extended amount of time, since the benefits of bisphosphonate therapy are well established.<sup>[3]</sup> Some of the oral diseases such as periapical pathoses, sinus tracts, purulent periodontal pockets, severe periodontitis and active abscesses which involve the medullary bone, may cause osteonecrosis by themselves. Such cases should be treated immediately.<sup>[2]</sup>

*Management of periodontal disease:*

Even though there are potential adverse effects of bisphosphonate therapy, still the use of these drugs are more beneficial in periodontal diseases. A nonsurgical therapy should be combined with a prolonged phase of initial therapy for observation. If the disease not resolve, surgical treatment should be aimed primarily and bone recontouring should be considered.<sup>[2]</sup>

#### *Oral and Maxillofacial Surgery:*

In the maxillofacial complex osteonecrosis can arise as a complication of several therapeutic regimens. In particular, osteoradionecrosis is a distinct type of osteonecrosis that results as a complication of high-dose radiation therapy, whereas osteomyelitis can cause osteonecrosis from microbial invasion bone. Steroid-induced osteonecrosis may be found less commonly.<sup>[3]</sup> Furthermore, rather than necrotic bone, current evidence supports an infectious and perhaps immunologic underlying cause for BJON.<sup>[19]</sup> Before starting bisphosphonate therapy, the patient should be referred for a thorough dental evaluation to identify and treat any potential sources of infection. The dentist should provide oral hygiene instructions and ensure dental prophylaxis is done.<sup>[3]</sup>

Consultation with a surgeon or dentist, who is familiar with the care of patients being treated for malignancy, is suggested if osteonecrosis is suspected.<sup>[1]</sup> Patients receiving treatment with these medications have been found to be at risk of experiencing delayed healing from tooth extractions and spontaneous soft-tissue breakdown leading to intraoral bone exposure.<sup>[12]</sup> Place the patient on a broad spectrum antibiotic prior to beginning a dental procedure and continue the antibiotic for a week.<sup>[1,2]</sup>

Patients with mild, asymptomatic or stage 1 disease may benefit from use of antimicrobial rinses such as 0.12% chlorhexidine, while a patient with exposed bone associated with pain and / or secondary infection of stage 2 disease will require oral antimicrobial rinses combined with antibiotic therapy based on culture and sensitivity tests.<sup>[3]</sup>

#### *Implantology:*

Limited data is available regarding the effects of implant placement in patients taking bisphosphonates. Furthermore, treatment plans for patients taking bisphosphonates should be considered carefully, since implant placement requires the preparation of the osteotomy site.<sup>[2]</sup> The dentist and the patient should discuss the risks, benefits and treatment alternatives, which may

include but not limited to periodontal, endodontic or non implant prosthetic treatments. Maintenance of implants should follow accepted mechanical and pharmaceutical methods to prevent peri-implantitis, with regular monitoring of the patient.<sup>[2]</sup>

In one study, the analysis suggests that the placement of an implant may be considered as a safe procedure in patients taking oral bisphosphonates for <5 years with regard to the occurrence of BJON, since in these studies no BJON has been reported.<sup>[20]</sup> Long term bisphosphonates use should be treated with caution. Well controlled, prospective clinical trails of its effects on bone are warranted to determine the risk of such complications.<sup>[21]</sup>

#### *Endodontics:*

Incorporating endodontic treatment is preferable over surgical intervention. Paraendodontic surgical procedures should be guided by the same recommendation as is used for any oral and maxillofacial surgical procedure described above.<sup>[2]</sup>

#### *Prosthodontics:*

All routine restorative procedures can be carried out. No evidence suggests the development of BJON by malocclusion or masticatory forces.<sup>[2]</sup> Patients with removable dentures should be examined for areas of mucosal trauma, especially along the internal mylohyoid ridge area. If BJON has already developed, dental management will depend on the severity of the lesion. In such patients, eliminating pain, controlling soft and hard tissue infections and minimizing progression of osteonecrosis should be the objective.<sup>[3]</sup>

Cessation or interruption of bisphosphonate therapy may be considered in severe cases. However, consultation between the dentist and the medical oncologist is recommended.<sup>[1]</sup>

#### **Conclusion:**

Routine dental treatment generally should not be modified solely on the basis of oral bisphosphonate therapy, a thorough medical history is essential. The dentist and physician managing the patient must adopt an interdisciplinary approach that will result in the formulation of an effective patient – specific management protocol.<sup>[3]</sup> The dentist's role as part of the medical treatment team is particularly important to enhancing the quality of life for these often very ill patients.<sup>[4]</sup> Close follow-up every three to four months is imperative to track the progress of the disease and to be on the lookout for any side



effects that may arise from bisphosphonate therapy.<sup>[4]</sup>

#### Key messages

- Dental practitioners need to be aware of the association between bisphosphonate treatment and delayed wound healing and osteonecrosis of the jaws.
- Treatment and prevention of osteoporotic fracture is a subject of increasing public health importance with large scale clinical and economic implications.

#### References:

1. Kurtzman GM, Silverstein LH, Peden J, Shatz PC. Implications of Bisphosphonate Use for the dentist: An Introduction. *Dent Today* 2006;25(6):80,82-5.
2. Association Report. Dental management of patients in receiving oral bisphosphonate therapy. Expert panel recommendations. *J Am Dent Assoc.* 2006;137(8):1144-50.
3. J. Sarin, SS De Rossi, So Akintoye. Updates on bisphosphonates and potential pathobiology of bisphosphonate – induced jaw osteonecrosis. *Oral Diseases* 2008; 14(3):277-85.
4. Michael RM, Joseph E, Margarone, John H, Campbell and Alfredo A. Bisphosphonate associated osteonecrosis of the jaws. A review of current knowledge. *J Am Dent Assoc* 2005;136(12):1669-74.
5. Adamo V, Caristi N, Sacca MM and et al. Current knowledge and future directions on bisphosphonate – related osteonecrosis of the jaw in cancer patients. *Expert Opin Pharmacother* 2008;9(8):1351-61.
6. Migliorati CA. Bisphosphonates and oral cavity avascular bone necrosis. *J of Clin Oncol* 2003;21:4253-4.
7. Sarasquete ME, Gonzalez M, San Miguel JF, Garcia – Sanz R. Bisphosphonate – related osteonecrosis: genetic and acquired risk factors. *Oral Dis* 2009; 15(6):382-7.
8. PierFranco C, Valentina G. Safety of Intravenous and Oral Bisphosphonates and compliance with Dosing Regimens. *The Oncologist* 2004;9(4):28-37.
9. N J Shaw, N J Bishop. Bisphosphonate treatment of bone disease. *Arch Dis child* 2005; 90:494-99.
10. Tripathy D, Lichinitzer M, Lazarev A, and et al. Oral ibandronate for the treatment of metastatic bone disease in breast cancer: efficacy and safety results from a randomized double blind, placebo-controlled trial. *Journal of clinical oncology* 2010;28(22):3548-51.
11. Crepin S, Laroche ML, Sarry B, and Merle L. Osteonecrosis of the jaw induced by Clodronate, an alkylbisphosphonate: Case report and literature review. *Eur J Clin Pharmacol* 2010; 66(6): 547-54.
12. M. Gnant. Bisphosphonates in the adjuvant treatment of early breast cancer. *Breast Cancer Research* 2009; 11(1): S17doi:10.1186/bcr 2278.
13. Umland EM, Boyce EG. Risedronate: a new oral bisphosphonate. *Clin Ther* 2001; 23(9): 1409-21.
14. Sciencedaily. Long term use of oral bisphosphonates may double risk of esophageal cancer. *Health and Medicine* 2010. Available at <http://www.sciencedaily.com/releases/2010/09/10090219327.htm>
15. Green J, Czanner G, Reeves G, Watson J, Wise L, Beral V. Oral bisphosphonates and risk of cancer of oesophagus, stomach, and colorectum: Case-control analysis within a UK primary case control. *BMJ* 2010;341:c4444.
16. Janis Kelly. H. pylori Suspected in Oral Bisphosphonate Intolerance, SSc Stomach Problems, 2008. Available at <http://www.mskreport.com/articles.cfm%3FarticleID%3D3228>
17. Jeffcoat M, Nelson BW. Osteonecrosis of the jaw: Balancing the benefits and risks of oral bisphosphonates treatment for osteoporosis. *Academy of General Dentistry*, 2008:96-102.
18. Jeffcoat MK. Safety of oral bisphosphonates: controlled studies on alveolar bone. *Int J Oral Maxillofac Implants* 2006;21:349-53
19. Wimalawansa SJ. Bisphosphonate – associated osteomyelitis of the jaw: guidelines for practicing clinicians. *Endocr Pract* 2008;14(9):1150-68.
20. Madrid C, Sanz M. What impact do systemically administered bisphosphonates have on oral implant therapy? A systemic review. *Clin Oral Implants Res* 2009;20(4):87-95.
21. Wang HL, Weber D, Mc Cauley LK. Effect of long-term oral bisphosphonates on implant wound healing: literature review and a case report. *J Periodontol* 2007;78(3):373-6.

Source of Support: Nil

Conflict of Interest: No Financial Conflict

